



International Journal of General Medicine & Surgery

Available Online: <https://ijgms.edwiserinternational.com>

A Case Report on Tuberculous Meningitis

Hassan M*, Madani M, Ali Khan MS, Omer M and Mateen M

Department of Pharmacy Practice, Nizam Institute of Pharmacy Educational, Hyderabad, India

Article info

Received 16 August 2019

Revised 05 September 2019

Published 12 September 2019

*Corresponding author: Hassan M, Department of Pharmacy Practice, Nizam Institute of Pharmacy Educational, Hyderabad, India; E-mail: drmh09@gmail.com

Abstract

Tuberculous meningitis is one of the most common type of Central Nervous System Tuberculosis which is an infection of the Meninges. It is most commonly caused by Mycobacterium Tuberculosis. It can be Acute or Chronic and leads to increase pressure within the skull which results in severe nerve and brain tissue damage. In this case, the patient is having Tuberculous Meningitis along with coexisting illness such as Hypertension, Type 2 Diabetes Mellitus, Hypothyroidism, Chronic Kidney disease and Pott's Spine. Appropriate treatment was provided to the patient.

Keywords: Sensorium; Tuberculous Meningitis; Pott's Spine; Tuberculomas; Meningismus

Introduction

Tuberculous Meningitis is an infection of the Meninges (Tissues Covering the Brain and Spinal Cord). It is due to the presence of granulomatous inflammation which leads to the inflammation of the Cerebral Leptomeninges [1,2]. Tuberculous Meningitis is caused by *Mycobacterium Tuberculosis/Koch Bacilli* [3]. This bacterium is known to cause Tuberculosis [1] an infectious disease that usually affects the lungs [3,4] and it is a communicable infectious disease [3,5]. It is transmitted via the respiratory route and it mainly affects the lungs but can spread through blood stream and lymphatic system to the brain, bones, eyes and skin [6].

Tuberculous Meningitis is developed by two steps. *Mycobacterium Tuberculosis* enters the human body via droplet inhalation. Localized infection rapidly increases in the lungs and spreads to regional lymph nodes [7] and enters bloodstream and travels to other areas of the body. When the bacteria travel to the Meninges (layers protecting the Brain) [8] and brain tissue, microtubercles are formed. These Microtubercles can burst and causes Tuberculous Meningitis. This can be acute or chronic and leads to

increased pressure within the skull which results in severe nerve and brain tissue damage [9].

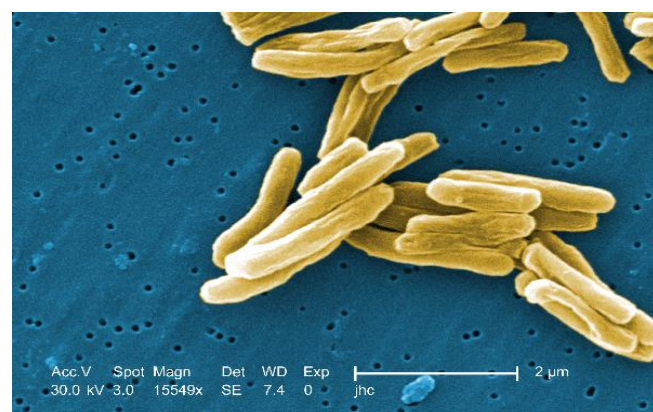


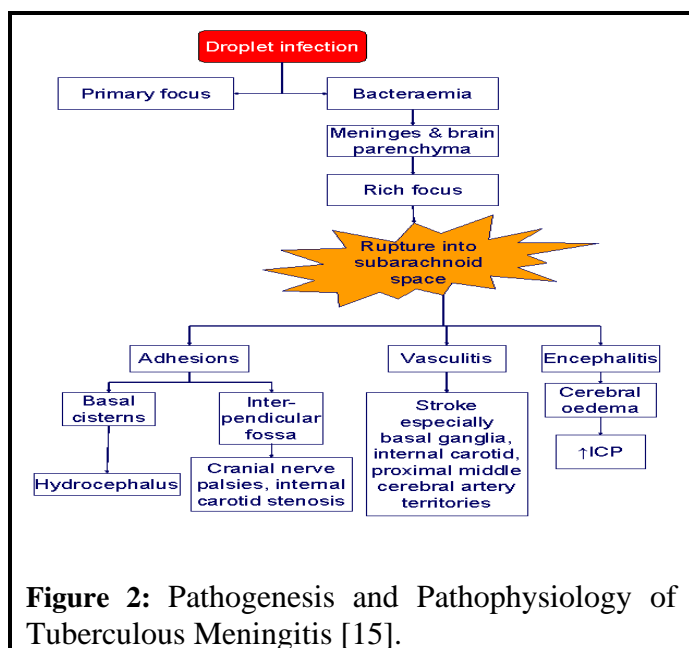
Figure 1: Under a high magnification of 15549x, this digitally-colored, scanning electron microscopic (SEM) image depicted a number of Gram-positive, *Mycobacterium tuberculosis* bacteria. As an obligate aerobic organism, *M. tuberculosis* can only survive in an environment containing oxygen. This bacterium ranges in length between 2 - 4 μm , and a width between 0.2 - 0.5 μm [12].

The *Mycobacterium Tuberculosis* bacilli has a structural component known as Tuberculostearic acid [10] (IUPAC: 10-Methyloctadecanoic acid) [11] (Figure 1).

Pathophysiology

During the initial stage the *Mycobacterium Tuberculosis* bacilli enters the human body by droplet inhalation, the alveolar macrophage being the initial point of infection. Localized infection escalates within the lung and disseminates to regional lymph nodes producing the primary complex. During this stage, there is a presence of short but significant bacteremia that can seed *Tubercle bacilli* to other organs in the human body. In those persons who develop Tuberculous Meningitis, small subpial or subependymal foci called rich foci are formed by the bacilli seed to the meninges or brain parenchyma [7,13] after the original pathological studies of Rich and McCordick [14].

During the second stage there is increase in the size of the rich focus until it ruptures into the subarachnoid space [7,13]. This indicates the onset of meningitis, which if left untreated, results in severe and irreversible neurological pathology [13]. Inflammation is due to development of a thick gelatinous exudate which infiltrates the cortical or meningeal blood vessels [7] (Figure 2).



This exudate progresses and extends along small proliferating blood vessels with the development of focal and diffuse ischemic and infarction of brain due to vasculitis. Entrapment of large cerebral arteries, and

vasculitis of large arteries, results in infarction. The exudate envelops the arteries and cranial nerves, which results in obstruction of the flow of cerebrospinal fluid at the level of the tentorial opening, which leads to hydrocephalus. Granulomas can combine to form tuberculomas.

Hydrocephalus and tuberculoma are Complications of Tuberculous Meningitis [16]. Multiple small cerebral and spinal tuberculomas are seen when tuberculous meningitis is a sign showing the existence of military tuberculosis [17]. The bacilli can also cross the Blood Brain Barrier and enter the Cerebro Spinal Fluid (CSF), which helps in the regulation of intracranial pressure and acts as hydraulic shock absorber [8,18], causing Blood borne spread of Tuberculous Meningitis.

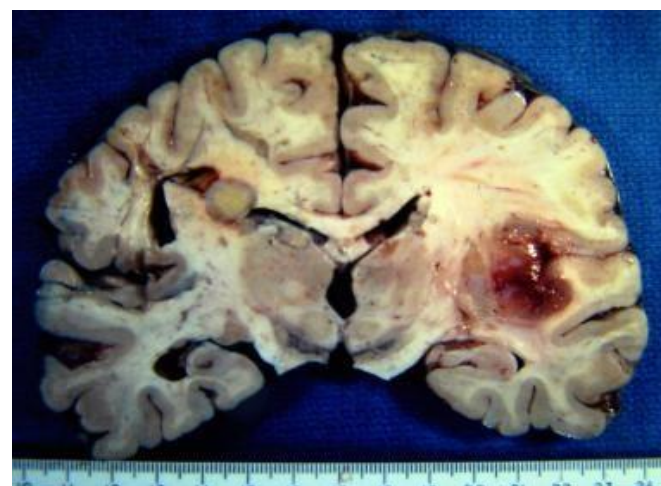

Figure 2: Tuberculoma is the round grey mass in the left corpus callosum. The red meninges on the right are consistent with irritation and probable meningeal reaction to tuberculosis. Courtesy of Schelper et al. [19].

Signs and Symptoms

- ✓ Fever and Chills
- ✓ Altered Sensorium
- ✓ Photophobia (Sensitivity to Light)
- ✓ Severe Headache
- ✓ Stiff Neck (Meningismus)
- ✓ Agitation
- ✓ Unusual Posture
- ✓ Fatigue
- ✓ Lethargy
- ✓ Unconsciousness
- ✓ Loss of appetite
- ✓ Tiredness

Risk Factors [9,20]

- ✓ HIV/AIDS
- ✓ Excessive ALCOHOL Use
- ✓ Weakened Immune System

Case Report

A 63-year old female patient was admitted to neurology department of hospital complaining of altered sensorium and headache for 2 days.

History

Known case of hypertension, type 2 diabetes mellitus, hypothyroidism, chronic kidney disease, bronchial asthma, pott's spine which was diagnosed 2 weeks ago and history of tubectomy (30yrs ago).

Past Medication History

Hypertension—tab. dilmip 10mg BD, tab. rosdar 10 mg OD, tab. dytor 20 mg ½ tab OD.

Type 2 Diabetes Mellitus—insoman comb 15–20 units.

Hypothyroidism—tab. thyronorm 125mg OD.

Social History

Non-Alcoholic, takes poor diet, decreased sleep & appetite.

Presentation of Case

For 2 days, the patient complained of altered sensorium along with headache. Patient was diagnosed with pot's spine 2 weeks ago.

Investigations

1st day: Haemoglobin, Red blood cells, packed cell volume levels were low, blood urea, creatinine, thyroid stimulating hormone levels were high, Blood pressure and pulse rate were Normal. Erythrocyte sedimentation rate was increased.

2nd day: Haemoglobin, Red blood cells, packed cell volume levels were low, blood urea, creatinine levels were high.

3rd day: Haemoglobin, Red blood cells, packed cell volume levels were low, blood urea, creatinine levels were high.

4th day: Haemoglobin, Red blood cells, packed cell volume levels were low, blood urea, creatinine levels were high.

Treatment

She was prescribed with inj. Monocef 1gm iv BD, inj. Decadan 8mg iv TID for 9 days.

2nd day: tab. Thyronorm 12.5mcg oral OD, inj. Heparin 5000U s/c TID, inj. Otski 1 amp iv OD, tab. Benadon 40mg oral OD, inj. Glevo 500 mg iv OD, tab.

- ✓ Diabetes Mellitus
- ✓ Immigrants
- ✓ Children Less than 5 yrs of Age
- ✓ Advancing Age

Rifampicillin 600 mg oral OD, tab. Isoniazid 300 mg oral OD, tab. Ethambutol 400mg oral OD, tab. Pyzina 700 mg oral OD for 8 days were prescribed. 3rd day: inj. Optineuron 1amp iv OD for 7 days were prescribed.

5th day: inj. Labetelol 10mg iv SOS, tab. Telma 40mg oral OD, tab. Cinod 10mg oral OD for 5 days were prescribed.

6th day: tab. Amlong 10 mg oral BD for 4 days was prescribed.

7th day: syp. Potklor 10ml oral TID, tab. Mucinac 1200 mg oral BD for 3 days were prescribed. 9th day: tab. Rifagut 400mg oral BD was prescribed.

Discussion

Tuberculous Meningitis is an infection of the Meninges caused by Mycobacterium Tuberculosis [1,2]. It is mostly common in children and older patients. In this case, patient was diagnosed with Tuberculous Meningitis, Hypertension, Type 2 Diabetic Mellitus, Hypothyroidism, Chronic Kidney disease. Treatment for current condition includes Antibiotics inj. Monocef 1gm BD, inj. Glevo 500 mg OD, to prevent blood clot inj. Heparin 5000U TID, to reduce inflammation inj. Decadan 8 mg TID is given, It acts by entering the cells of target organ and binds to specific receptors in the cytoplasm, where steroid receptor complex becomes activated, this complex enters the nucleus and binds to specific site on DNA which regulates the protein synthesis and produces physiological response in then body, tab. Thyronorm 12.5mcg for hypothyroidism.

For the treatment of Tuberculous Meningitis, Tab. Rifampicillin 600mg OD—it acts by binding to bacterial DNA-dependent RNA polymerase and inhibits RNA synthesis. Tab. Isoniazid 300 mg OD—it acts by inhibiting biosynthesis of mycolic acids, which are essential constituents of the mycobacterial cell wall. Tab. Ethambutol 400 mg OD—it inhibits arabinosyl transferases that are involved in mycobacterial cell wall synthesis. Tab. Pyzina 750 mg OD—it inhibits mycobacterial mycolic acid biosynthesis. For the prevention of anemic conditions or blood disorders inj. Optineuron 1amp OD, tab. Benadon 40 mg OD is given, for development of body tissues inj. Otski 1amp BD is given, tab. Amlong 10mg BD, inj. Labetelol 10 mg SOS, tab. Telma 40 mg OD, tab. Cinod 10 mg OD are prescribed for Hypertension, tab. Rifagut is given

for the treatment of diarrhoea it acts by inhibiting the RNA synthesis and binds to the beta subunit of Bacterial DNA dependent RNA polymerase enzyme which results in the blockage of translocation step and prevents the multiplication of *Escherichia coli* bacteria, for potassium deficiency syp. Potklor 10 ml TID is given.

Conclusion

Proper information must be provided to the patient regarding her current medical condition along with the descriptions of drugs. Eradication of infection with amelioration of signs and symptoms. As the patient is hypertensive, dietary sodium intake must be restricted to 1.5 g/day, alcohol and smoking cessation. Reduction in the amount of sugar and protein intake to control diabetes mellitus and chronic kidney disease.

References

1. <https://medlineplus.gov/ency/article/000650.htm>
2. <https://www.medilexicon.com/dictionary/54120>
3. <https://www.medicalnewstoday.com/articles/8856.php>
4. Mohan H. Textbook of pathology. 7th Edn. Jaypee; Chapter 6, Inflammation and healing. 2014; pp: 49-152.
5. Morrison RT, Boyd RN. Organic Chemistry. 6th Ed. Pearson; Chapter 33, Lipids, Problem. 2007; pp:1300
6. French GL, Chan CY, Cheung SW, et al. Diagnosis of tuberculous meningitis by detection of tuberculostearic acid in cerebrospinal fluid. *Lancet* 1987; 330: 117-119.
7. <https://emedicine.medscape.com/article/1166190-overview#a2>
8. <https://www.meningitisnow.org/meningitis-explained/what-is-meningitis/types-and-causes/tb-meningitis/>
9. <https://phil.cdc.gov/details.aspx?pid=9997>
10. <https://muhammaddian.files.wordpress.com/2016/03/pharmacotherapy-handbook-9th-edition.pdf>
11. Tortora GJ, Derrickson B. Anatomy and Physiology. India Edn. Chapter 14, The Brain and Cranial Nerves. Wiley 2014; pp:440-445
12. https://archive.org/stream/BiochemistryByU.satyanarayana/Biochemistry_satyanarayana_chakrapani_cbbxch_djvu.txt
13. Thwaites G, Chau TT, Mai NTH, et al. Tuberculous meningitis. *J Neurol Neurosurg Psych* 2000; 68: 289-299.
14. Ilango K, Valentina P. Textbook of medicinal chemistry. 2nd Edn. Keerthi Publishers. Chapter 4 Anti TUBERCULAR agents; 2015; pp:69.
15. Rich AR, McCordick HA. The pathogenesis of tuberculous meningitis. *Bulletin John Hopkins Hospital* 1933; 52: 5-37.
16. Tai MLS, Tuberculous meningitis: Diagnostic and radiological features, pathogenesis and biomarkers. *Neurosci Med* 2013; 4: 101-107.
17. <https://www.aic.cuhk.edu.hk/web8/TB-meningitis.htm>
18. Garg RK, Malhotra HS, Jain A. Neuroimaging in tuberculous meningitis. *Neurol India* 2016; 64: 219-227.
19. <https://emedicine.medscape.com/article/1166190-overview#a3>
20. <https://www.healthline.com/health/meningitis-tuberculosis>

This manuscript was peer-reviewed

Mode of Review: Single-blinded

Academic Editor: Tobing D

Copyright: ©2019 Hassan M, et al. This article is distributed under the terms of the Creative Commons Attribution 4.0 International License (<http://creativecommons.org/licenses/by/4.0/>), which permits unrestricted use, distribution, and reproduction in any medium, provided you give appropriate credit to the original author(s) and the source, provide a link to the Creative Commons license, and indicate if changes were made

